

Young stroke 檢查流程

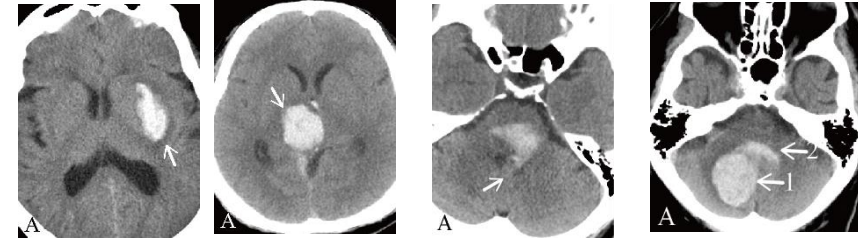
Symptoms of stroke

→ CT → ICH



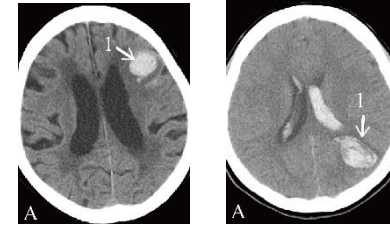
Deep ICH

always hypertension
CT is enough



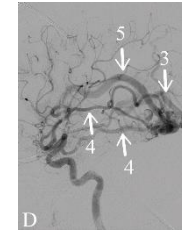
Lobar ICH

aged: amyloid angiopathy
CT is enough
young: vascular anomaly



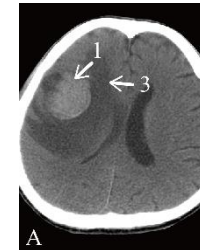Young stroke

vascular anomaly,
consider IV contrast
or CTA, even DSA

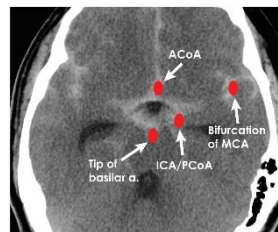


Acute ICH

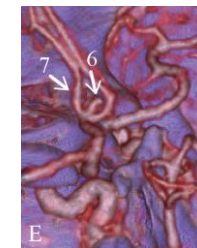
with peripheral
WM edema---tumor
bleeding,
consider IV contrast



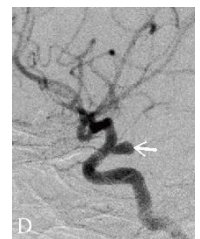→ SAH



CTA
to find aneurysm



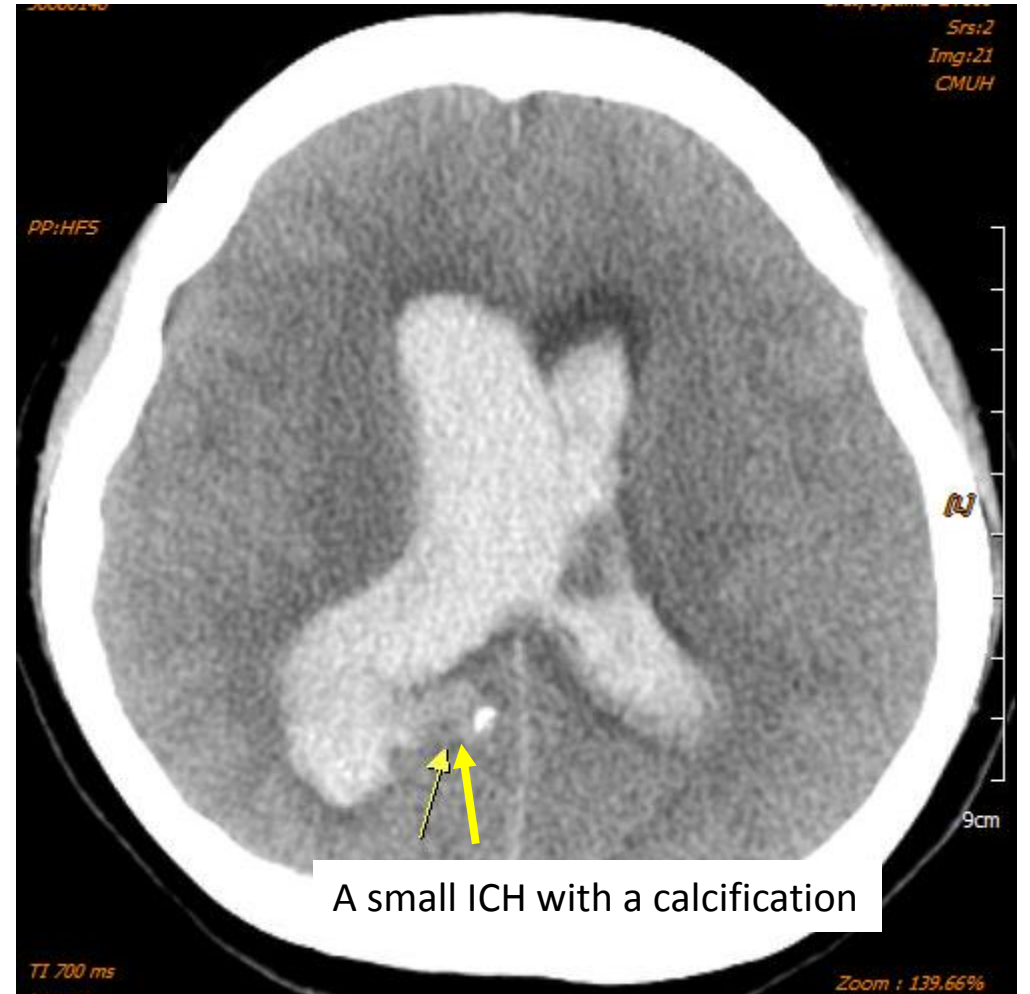
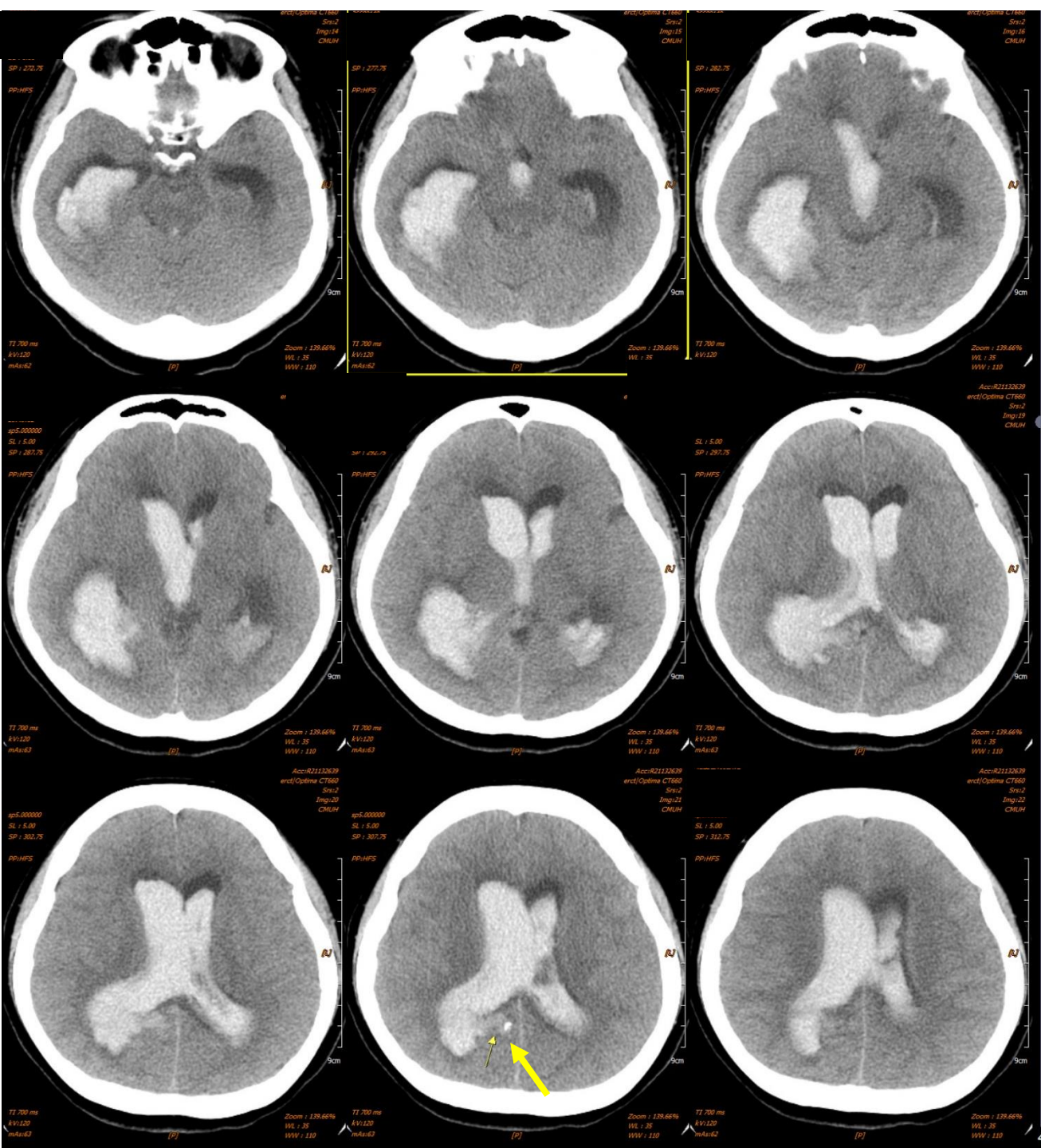
DSA
consider
embolization



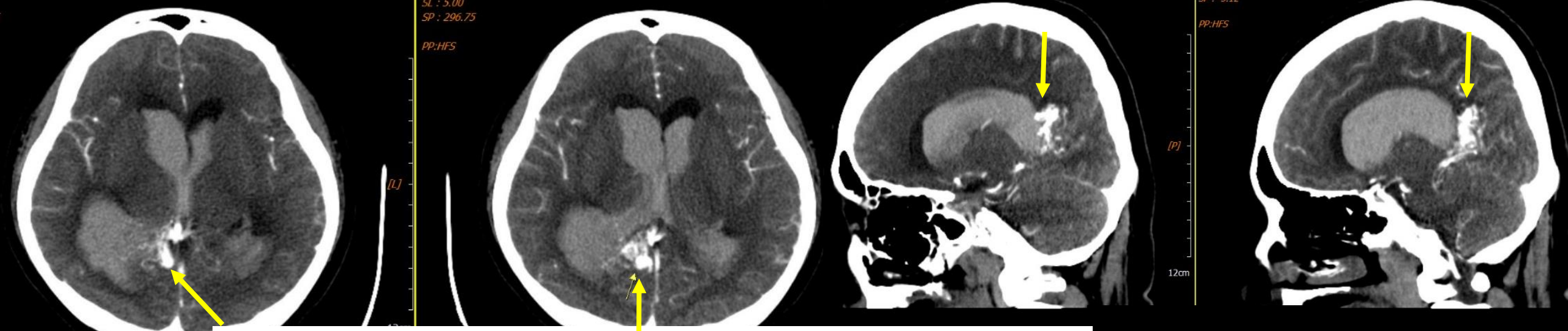
36680148 2020,11,11

F/31

sudden onset of consciousness lost and then
coma

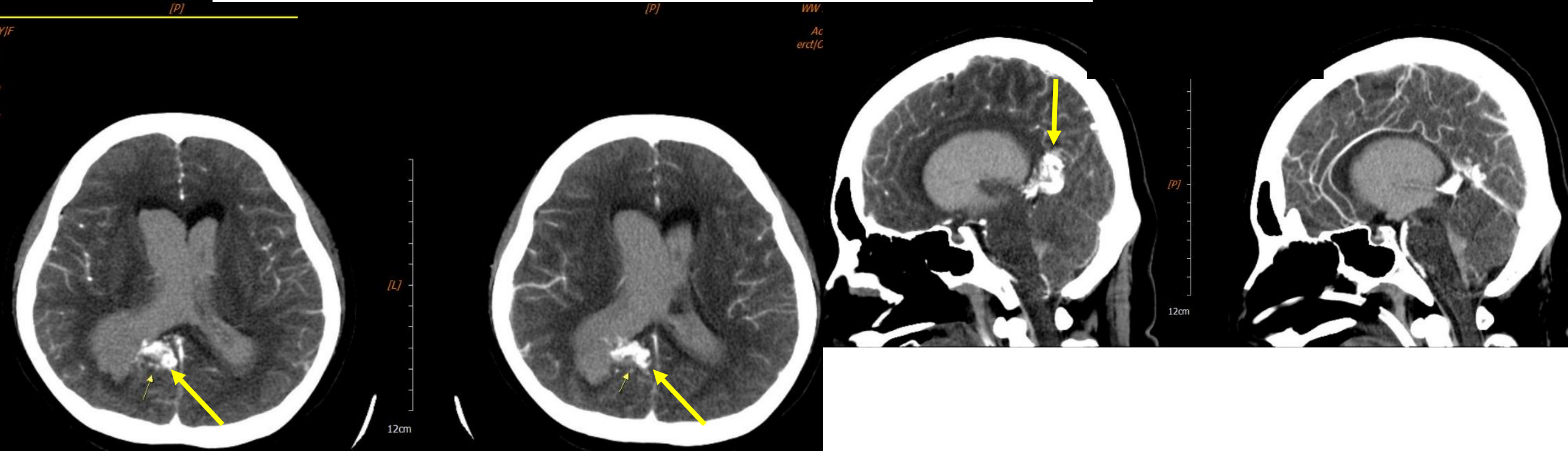


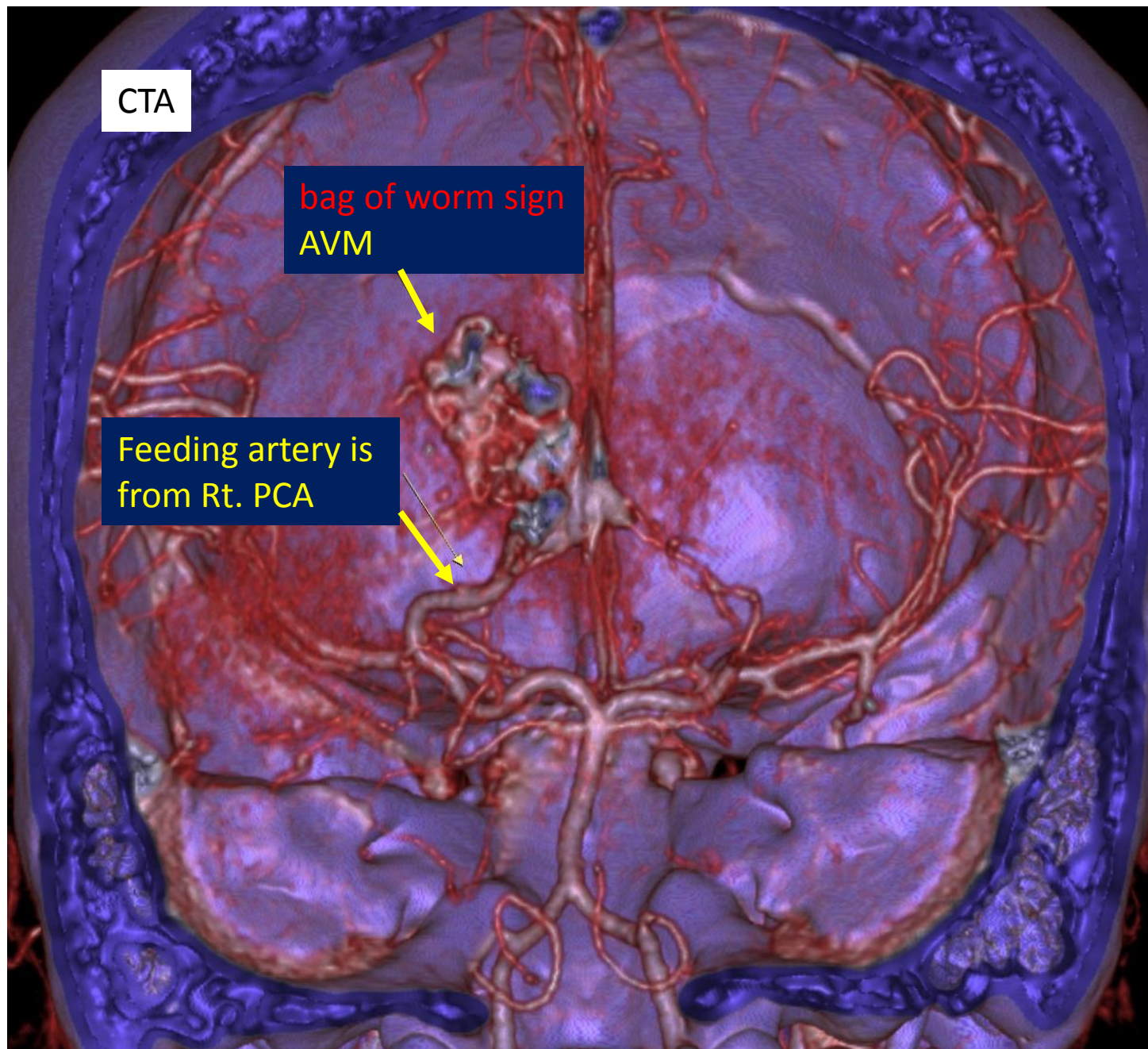
A small ICH with a calcification



A small ICH with a calcification
iv contrast enhancement:
abnormal vascularities (**bag of worm sign**), reflecting AVM, the bleeding source

(all are source images of CTA)





Clinical condition was poor,
no DSA was performed